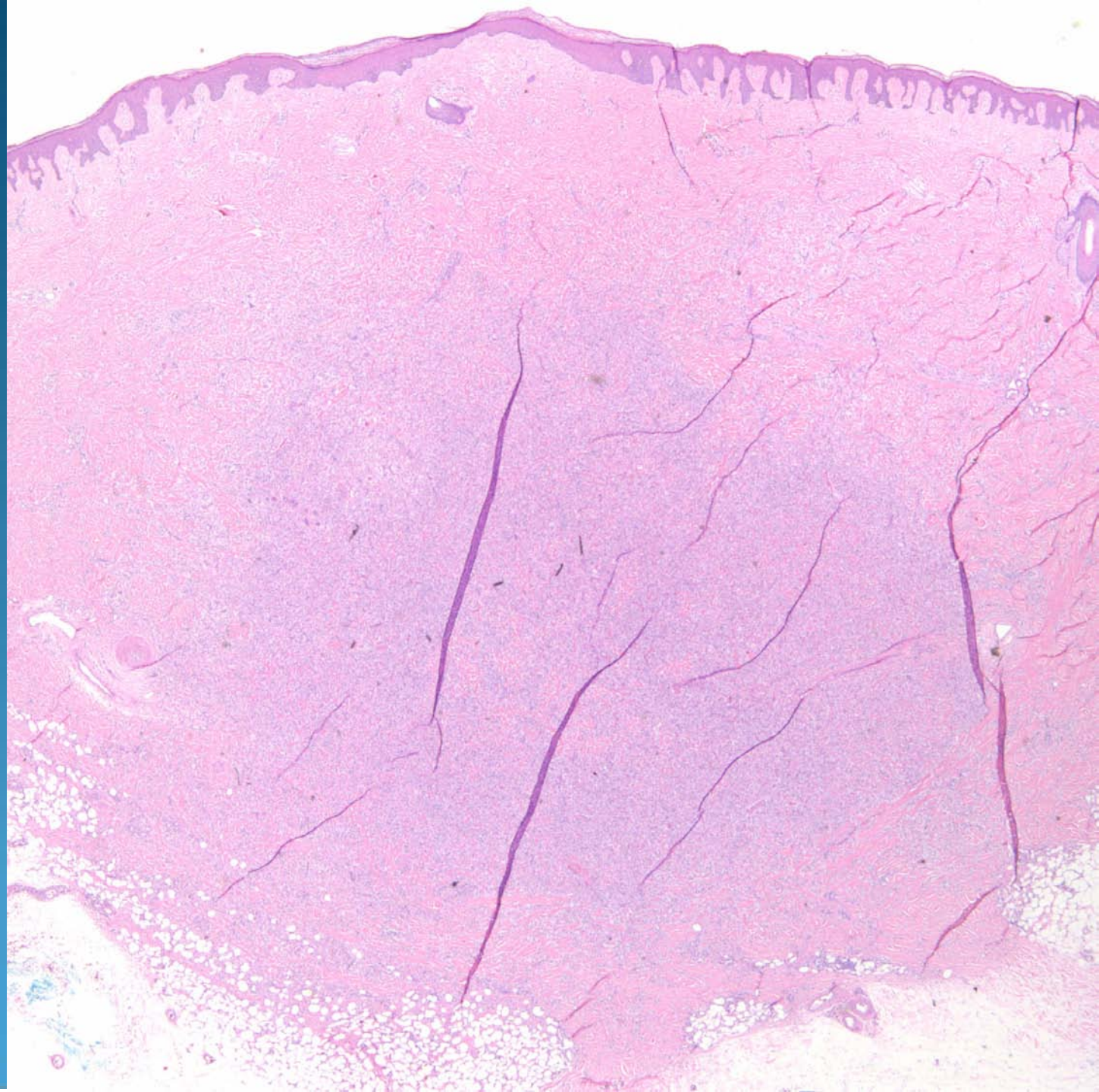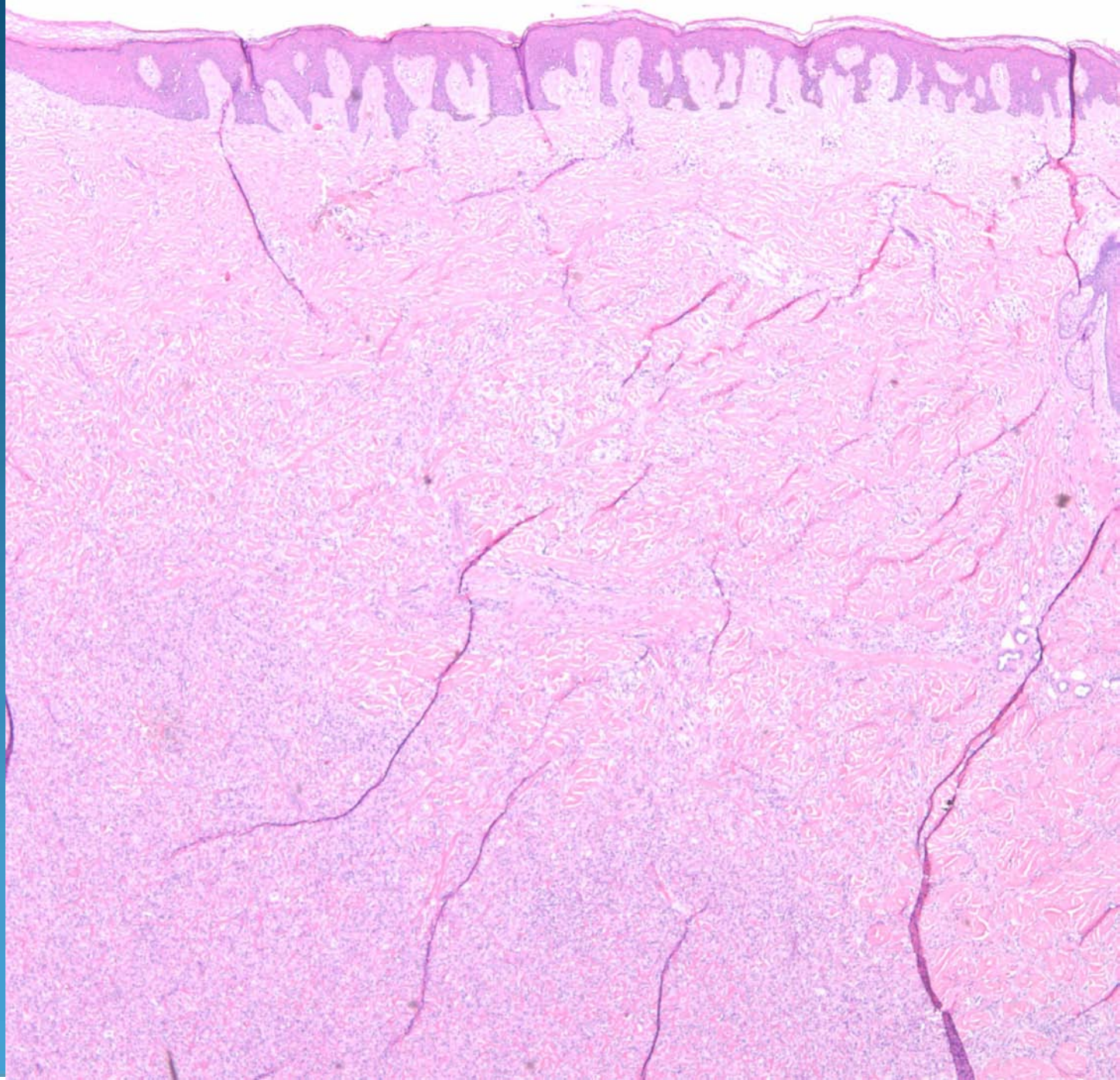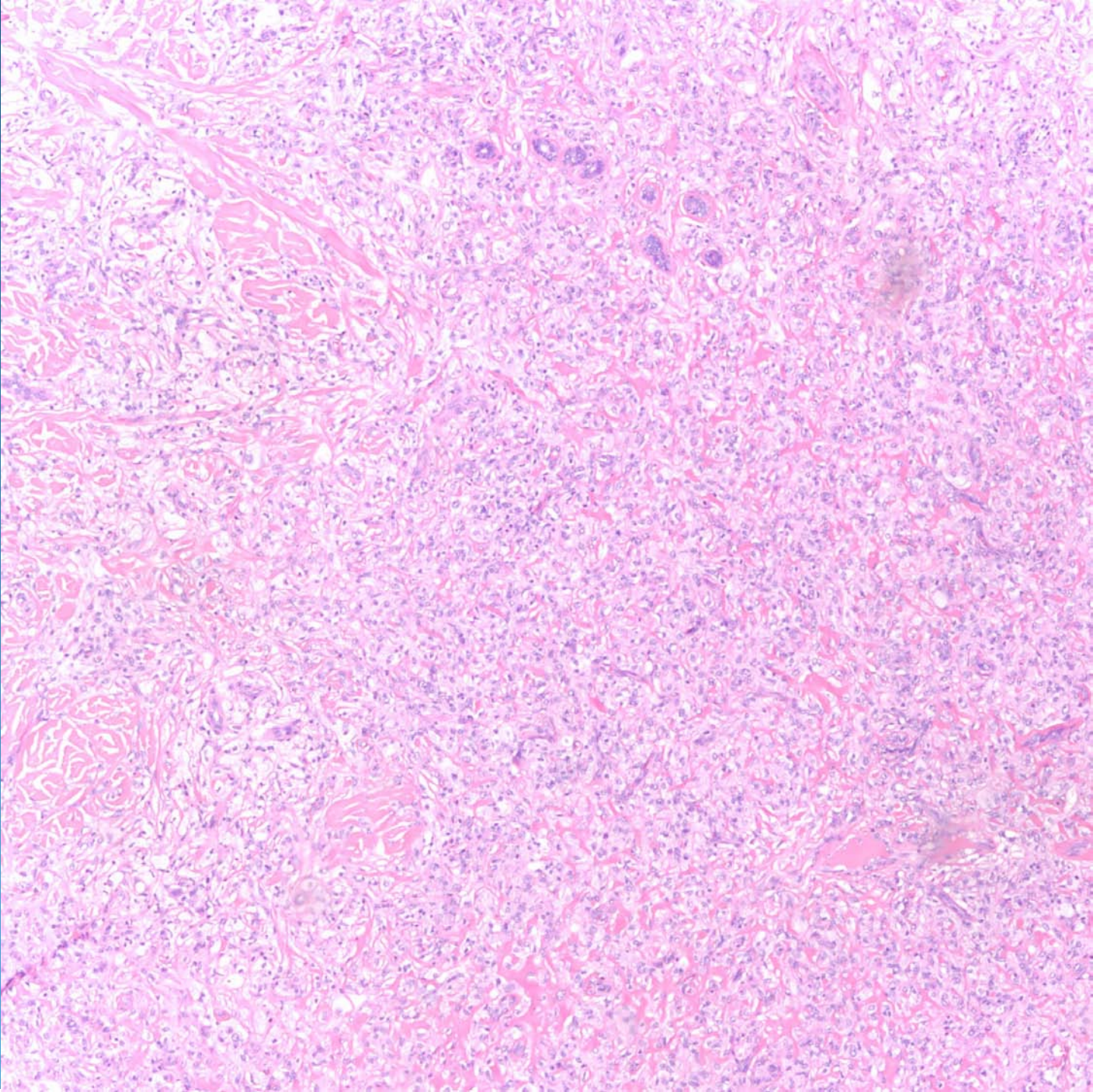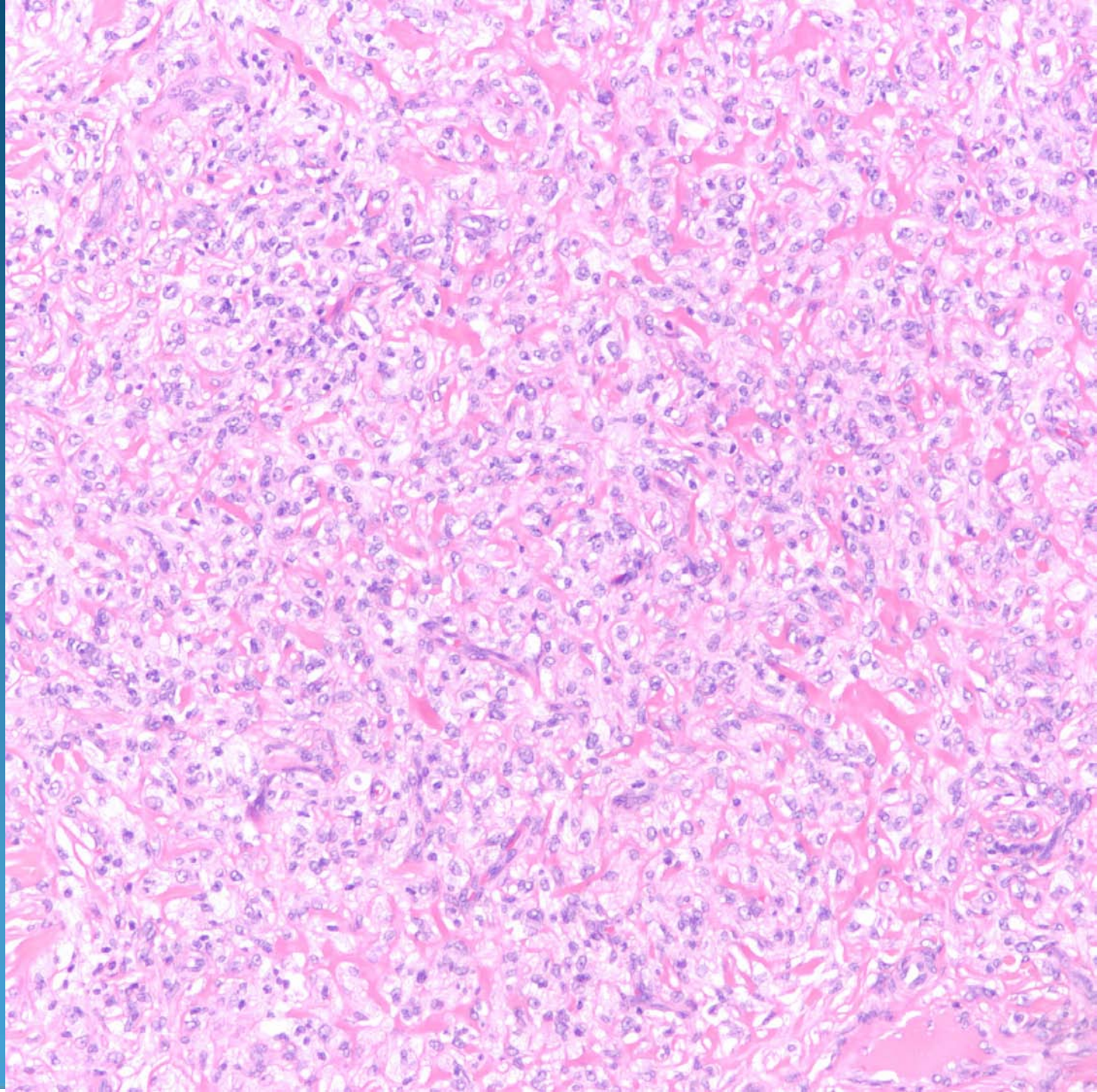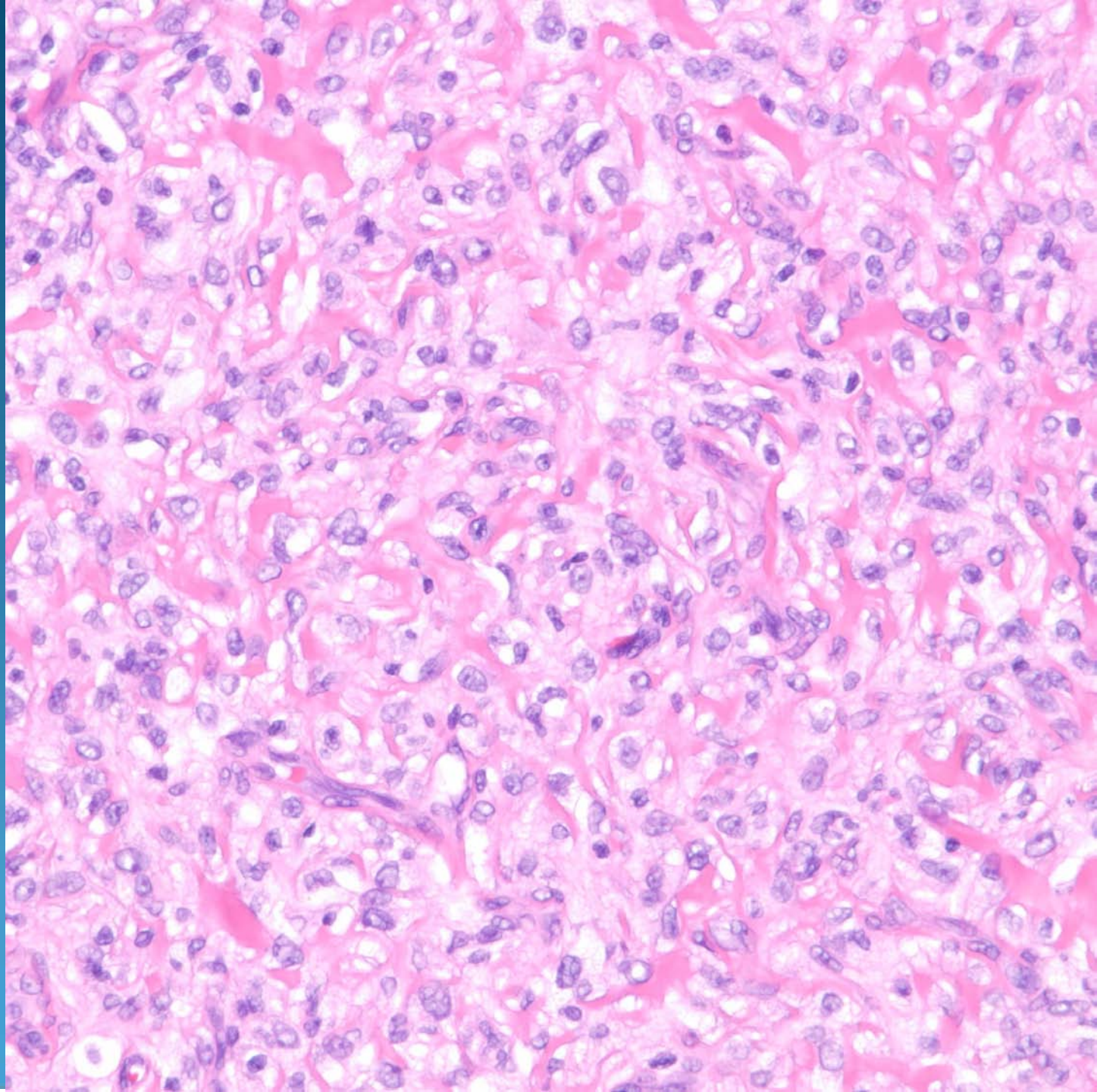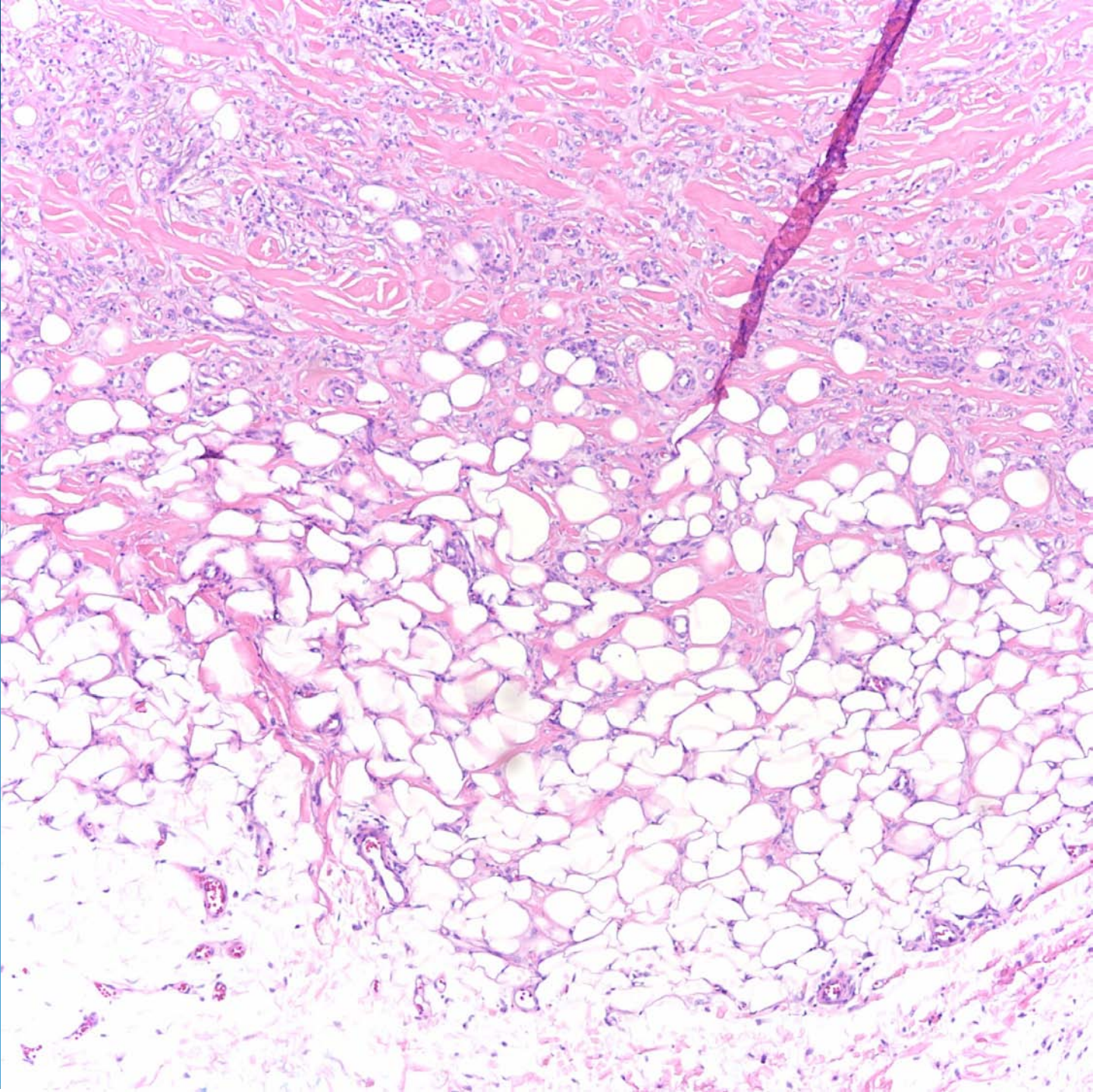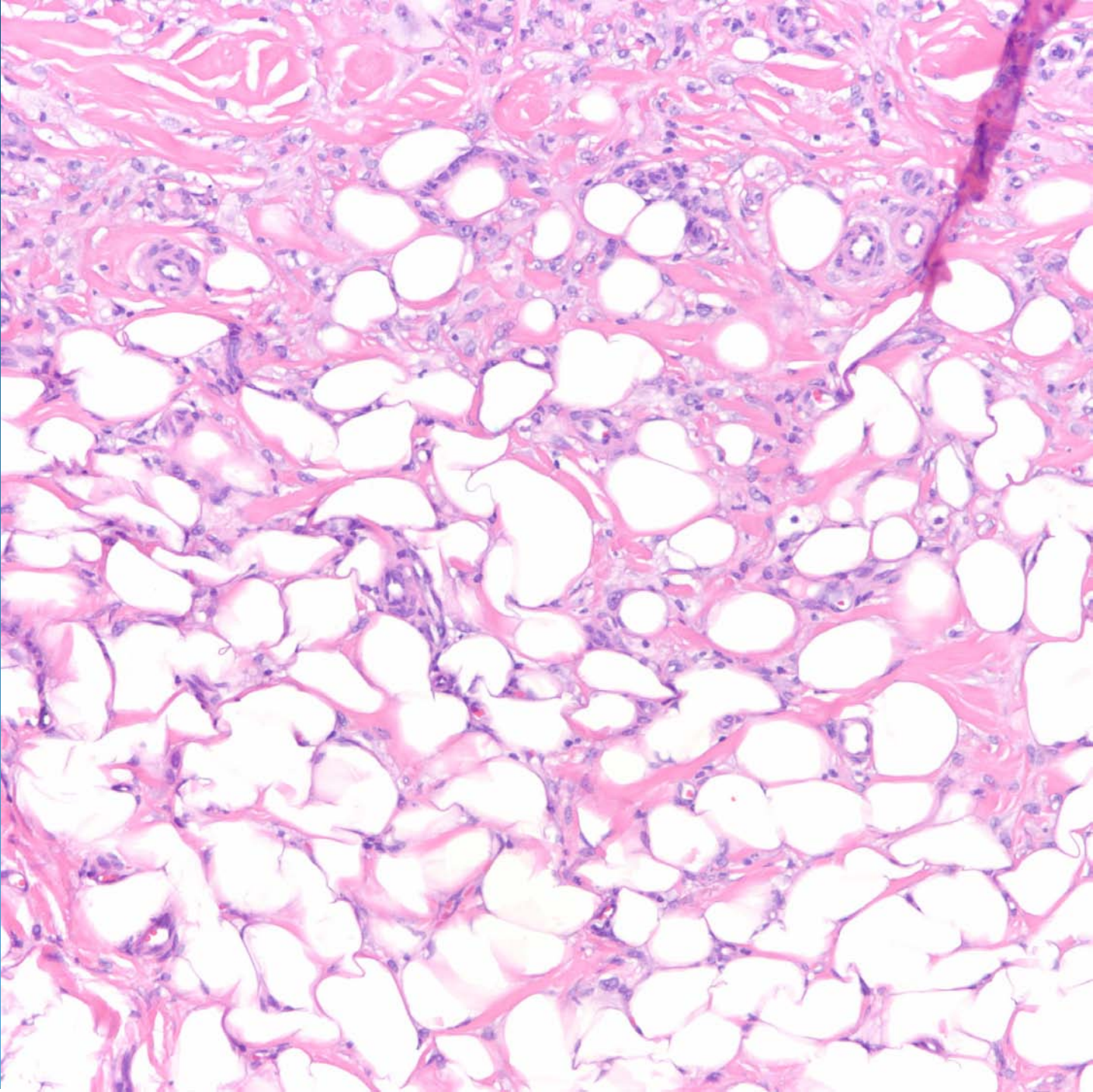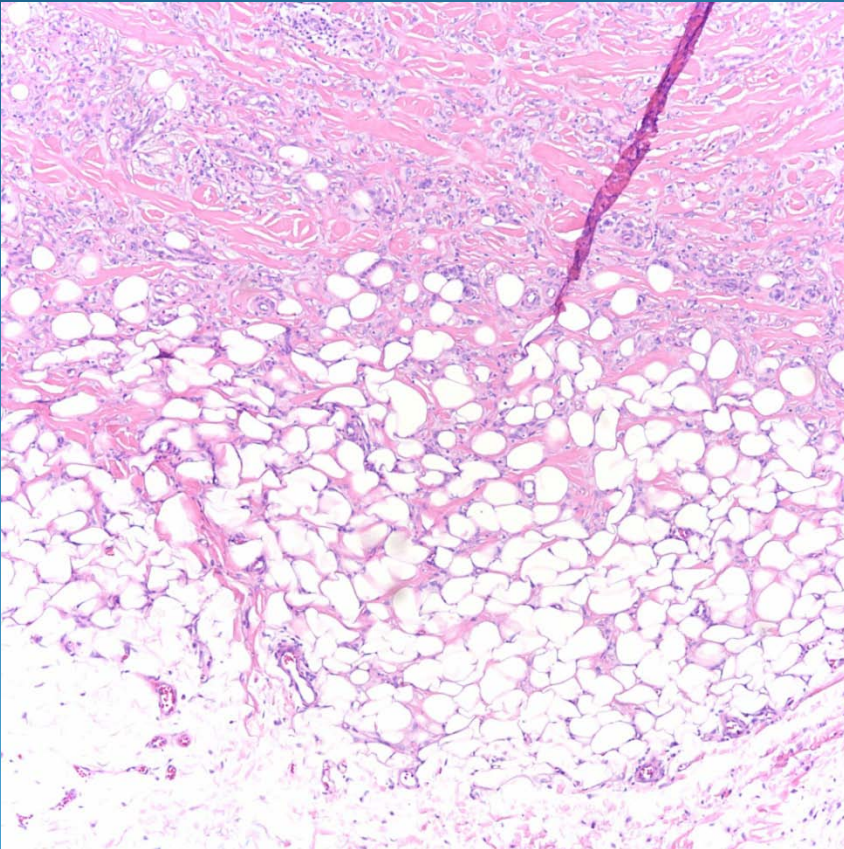


# Dermatofibroma, Xanthomatous Variant



# Pearls



- Cellular spindle cell tumor with epidermal hyperplasia and Grenz zone
- Cells have spindled and bubbly cytoplasm
- Look for “root-like” extension of cells into the fat, contrast with DFSP